

**Genital tract tuberculosis in a 42-year female masquerading as ovarian malignancy.**

**ABSTRACT.**

Female genital tuberculosis is one the known causes of infertility in the tropics. The symptom complex are diverse and it is one of the known causes of pyrexia of unknown origin. Instances of mimicry of ovarian cancer with raised CA125, have been reported. We present a case report in a 42-year-old woman with abdominal pain and progressive abdominal pain of 3 weeks durations, who had confounding symptom of raised CA125, forcing a presumptive diagnosis of ovarian cancer. She had exploratory total abdominal hysterectomy (TAH). The surgical findings and histopathological diagnosis were suggestive of tuberculosis, for which she is undergoing treatment and showing remarkable improvement.

**Key words:** *Genital, tuberculosis*

**INTRODUCTION:**

Tuberculosis (Tb) is a deadly chronic infection, presenting as progressive body wasting, pulmonary involvement is the rule, although every organ may be affected. (1-3). Female genital tuberculosis is often misdiagnosed due to non-specificity of symptoms (4-6) and the difficulty of isolating the mycobacteria in some instances. Infertility is the commonest presenting complain. (7). The causative organism is an obligate aerobe, *Mycobacterium tuberculosis* and two species *m tuberculosis* and *m bovis* are known to cause human disease. *M. tuberculosis* causes pulmonary disease and *M bovis* causes abdominal disease. (8). The bacteriology and pathogenicity are well documented elsewhere. The source of female genital tuberculosis is reported to be haematogenous (8, 9). Attah reported that the fallopian tube is the source of dissemination to the rest of the genital tract, but Turkmen et al who reviewed 1,548 cases occurring in Turkish women, found the endometrium was involved in 1,073 cases, fallopian tubes in 164 cases, cervix 157 and multiple sites 154. Namavar and colleagues found 73.03% endometrial location in their series while tubal involvement was 34.03%, ovarian involvement accounted for 12.9% and 2.4% cervical involvement (7). Aliyu et al also reported fallopian tube as the commonest site of genital tuberculosis (10). The clinical presentations are diverse (11) and may be very nonspecific. Qureshi et al in Pakistan reported infertility 42.5% as the chief presenting complain followed by abdominal pain 42% (12). Other symptoms in their studies included fever, ascites, irregular vaginal bleeding, oligomenorrhoea, chest pain and pain in the flanks (12). Infertility as the main presenting feature in genital tuberculosis was reported by many authors (5, 7, 12-24). Ovarian presentation with raised CA125 and therefore mimicry of ovarian cancer is a common way of presentation (25-27). It is therefore important to include tuberculosis in the differential diagnosis of ovarian cancer in the tropics when there is suspicion of ovarian cancer, even with raised CA125.

Diagnosis of female genital tuberculosis may be difficult because it is the paucibacillary form of the disease, smears and cultures from it are often negative (26). In some instances the researchers had to use polymerase chain reaction amplification of the mycobacterial DNA to support the clinical and histological diagnosis (25-27). Cervical tuberculosis is rare, but in one study in India it was diagnosed at Papanicolaou smear (Pap smear) and confirmed through biopsy (28). Instances of formation of tubo-ovarian abscesses calling for hysterosalpingographic examination have been reported (29) or presentation as acute pelvic inflammatory disease (30). In both cases patients were HIV positive. Other investigations normally done include trans vaginal scans, colposcopy, chest X rays, abdominal and pelvic CAT, Mantoux test and general laboratory tests (31). Liquid and solid tissues can be cultured to recover the organism and Ziehl Neelsen and Kinyoun special stains are used for

48 confirmation(8).There is need for a high index of suspicion in immigrant patients presenting in foreign  
49 locales with pelvic symptoms.

## 50 **CASE REPORT.**

51 **Case History:**A 42-year-old lady presented at the general outpatient department complaining of  
52 abdominal pain and progressive abdominal swelling of three weeks duration, she also experienced  
53 associated body weakness and easy satiety. There was no history of cough, haemoptysis, or night  
54 sweats. They was positive history of significant weight loss.

55 The findings on examination the abdomen were distension with tenderness on the left iliac region.  
56 Ascites was demonstrable by shifting dullness.

57 Her parity was p3+0.Pelvic examination revealed a bulky retroverted uterus with a tender irregular  
58 left adrenal mass and they was fullness of the pouch of Douglass.

## 59 **Radiology:**

60 **Chest X ray:** The chest X-ray was normal.

61 **Ultrasonography;** Initial abdominopelvic scan revealed, marked ascites with collapsed bowel loops.  
62 A bulky uterus was found with a myoma in the posterior myometrium measuring 3.8x 1.7 cm as well  
63 as a multicystic left adnexal mass. The largest cyst measuring 4.5x 4.2 cm.A diagnosis of suspected  
64 left ovarian malignancy was suggested.

65 **Laboratory Results:** The complete blood count result was, Total wbc 4.8 x10/dl, neutrophils 67%,  
66 lymphocytes 30%, eosinophils 2% and basophils 0.

67 The erythrocyte sedimentation rate was 121/mm. The serum electrolytes were normal, however  
68 CA125 was elevated, (449.9µm) normal range (0-35).

69 **Diagnosis:**Based on these findings a presumptive diagnosis of ovarian malignancy was made and  
70 the patient counselled for exploratory laparotomy..

71 **Surgery:** She had a staging total abdominal hysterectomy (TAH) plus bilateral salpingectomy and left  
72 sided oophorectomy.Intraoperative findings included 2.2 l of clear ascitic fluid and widespread  
73 seedlings in the pelvis and gut. The omentum was free of lesions, so infracolic omentectomy was not  
74 carried out

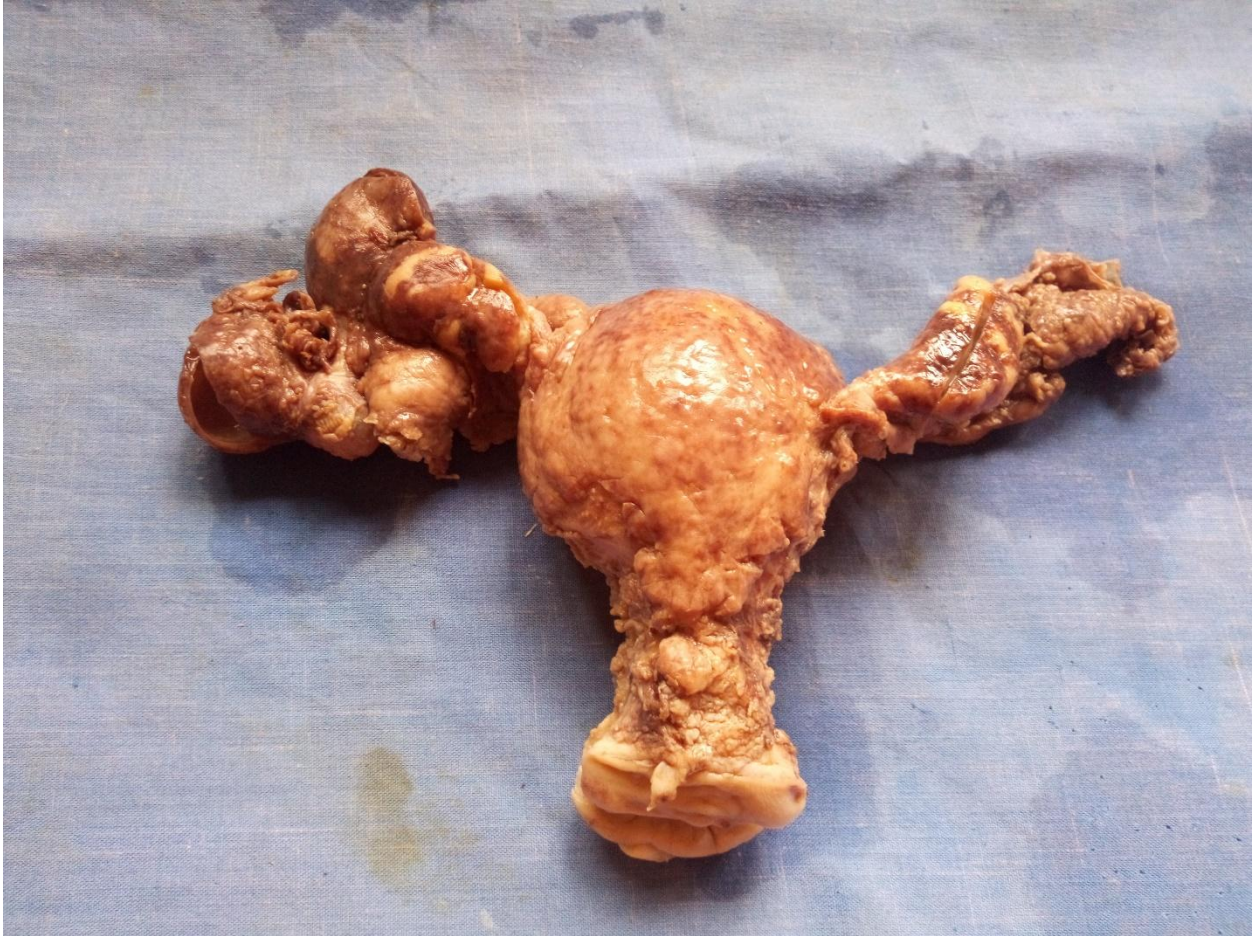## 75 **Histopathology:**

76 Gross: The TAH specimen measured 10x 5.5x4 cm, the external surface was studded with miliary  
77 size caseous nodules. They was left sided tubo- ovarian abscess,the right fallopian tube was equally  
78 enlarged,the left being more prominent. Caseous necrosis was seen in the left and right salpinx as  
79 well the left ovaries.Cut surfaces show cystic fallopian tubes and left ovary had thickened wall and  
80 caseous necrosis in some areas.They was an intramural myoma.The cervix and endometrium were  
81 not involved.

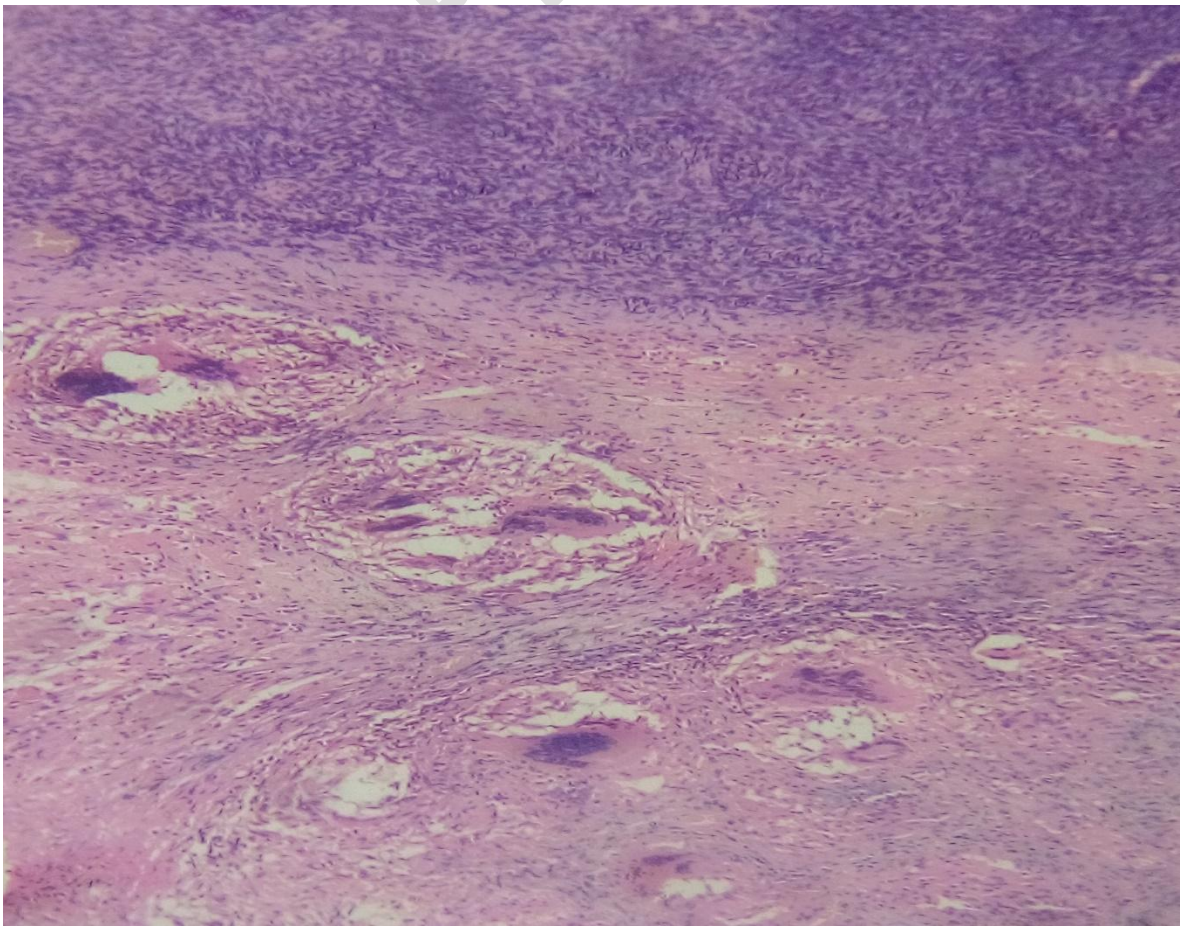
82 Microscopy:There were chronic granulomas with Langhans type giant cells seen in the left and right  
83 salpinx as well as the right ovariectomy specimen.

84 A diagnosis of chronic granulomatous inflammation most probably tuberculosis,was made. The Ziehl  
85 Neelsen stain for Mycobacteria was inconclusive.





**Figure 1:** TAH specimen showing tubo-ovarian abscesses the left > the right.

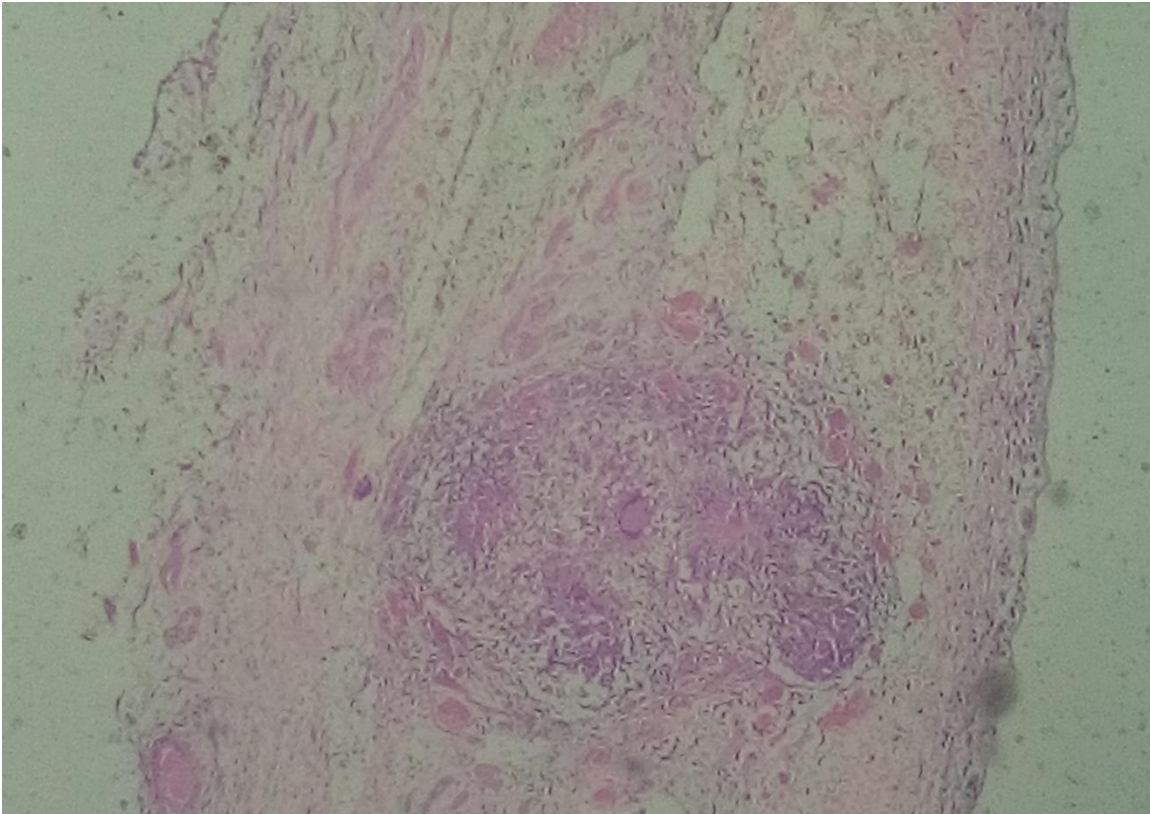


86  
87  
88  
89  
90  
91  
92  
93  
94  
95  
96  
97  
98  
99  
100



101  
102  
103  
104  
105

**Fig.2;Granulomata in the ovary,Langhans type giant cells, and necrotic areas(H&EX 400)**



114  
115  
116  
117  
118  
119

**Figure 3: shows granuloma in the wall of the fallopian tube.(H&E X400)**

120 The immediate post-operative period was uneventful but 3 weeks after discharge from the hospital, she  
121 complained of abdominal pain and swelling.an abdominopelvic scan was ordered which revealed hepato  
122 splenomegaly. Hepatitis b surface antigen was negative and HIV test was non-reactive. Ascitic fluid as  
123 sent for gene expert assay for tuberculosis but it turned out negative.

124 **Treatment and Outcome:**The respiratory physicians and public health physicians were called in to  
125 evaluate the patient and a diagnosis of genital tuberculosis with pelvic and peritoneal dissemination was  
126 made.

127 She was commenced on empirical tuberculosis therapy and has shown tremendous improvement.The Tb  
128 regimen chosen was the same as that normally used for pulmonary Tb. The treatment consisted of 2

129 months of intensive phase of oral isoniazid,rifampicin,pyrazinamide and ethambutol, followed by four  
130 months of continuation phase with isoniazid and rifampicin.She has completed the course of treatment  
131 and has shown remarkable improvement.She is currently on follow-up, which has been going on for the  
132 past four months.

## 133 **DISCUSSION**

134 The difficulty often encountered in the diagnosis of female genital tuberculosis(18, 31) was appreciated in  
135 the management of this patient. This informed the suggestion by Zhuchenco and group that the  
136 differential diagnosis of genital tuberculosis be approached in two steps;through the use of routine clinical  
137 examination and the study of antituberculous immunity(32).A combination of test often out of reach of the  
138 poor are required in the diagnosis of this disease(9, 21),yet tuberculosis is the disease of the poor. A case  
139 reported from Italy, had a Pap smear, culposcopy,trans vaginal scan, chest X-ray, abdominal and pelvic  
140 CAT scan, Mantoux test and other laboratory test.(31).In some instances the investigators had to culture  
141 tissue samples and amplified the mycobacterial DNA using polymerase chain reaction(29).There is  
142 therefore the need for us over here to always entertain a high index of suspicion and formulate a robust  
143 differential diagnosis that provides a quick definitive diagnosis at the cheapest cost.

144 The second confounding factor within the narrow scope of investigations that were carried out was the  
145 raised levels of CA125.It is important to note that CA125 is also raised in some benign conditions,  
146 including cases of female genital tract tuberculosis.(33),other conditions include, pelvic inflammatory  
147 disease,pregnancy,cirrhosis of the liver,endometriosis ectopic pregnancy, tubo- ovarian abscess, ovarian  
148 cyst hyperstimulation syndrome among others.(34).It is therefore important to always interpret raised  
149 CA125 in proper context with other clinical variables.The prevalence of Tb in the locality of this study is as  
150 yet unknown,but unpublished data suggest that as many as 44.6% of HIV patients attending clinic have  
151 tuberculosis.It therefore means efforts should be made towards improved diagnosis of extrapulmonary  
152 tuberculosis which is likely to accompany such high Tb. rate.

153 **CONCLUSION:**Most studies emphasized a strong clinico Pathologic and radiological interplay in the  
154 diagnosis of these caes.It is important to note that tuberculosis is ever present in our part of the world  
155 therefore among it systemic complications, genital tract disease should expected and sought out for

156 **CONSENT:**Patients personal data was anonymised and permission for the use of specimen  
157 photographs and histopathological photomicrographs was granted by the Department of  
158 Pathology,University of Calabar Teaching hospital.

159 **ETHICAL APPROVAL:** Approval was granted by the institutional review board.

160

## 161 **REFERENCES:**

- 162 1. Gelaw YA, Williams G, Soares Magalhaes RJ, Gilks CF, Assefa Y. HIV Prevalence Among  
163 Tuberculosis Patients in Sub-Saharan Africa: A Systematic Review and Meta-analysis. AIDS  
164 Behav. 2019;23(6):1561-75.
- 165 2. Said K, Verver S, Kalingonji A, Lwilla F, Mkopi A, Charalambous S, et al. Tuberculosis among HIV-  
166 infected population: incidence and risk factors in rural Tanzania. Afr Health Sci. 2017;17(1):208-  
167 15.
- 168 3. Crook AM, Turkova A, Musiime V, Bwakura-Dangarembizi M, Bakeera-Kitaka S, Nahiry-Ntege P,  
169 et al. Tuberculosis incidence is high in HIV-infected African children but is reduced by co-  
170 trimoxazole and time on antiretroviral therapy. BMC Med. 2016;14:50.
- 171 4. Bose M. Female genital tract tuberculosis: how long will it elude diagnosis? Indian J Med Res.  
172 2011;134:13-4.
- 173 5. Turkmen IC, Bassullu N, Comunoglu C, Bagci P, Aydin O, Comunoglu N, et al. Female genital  
174 system tuberculosis: a retrospective clinicopathological study of 1,548 cases in Turkish women.  
175 Arch Gynecol Obstet. 2012;286(2):379-84.

- 176 6. Hasanzadeh M, Naderi HR, Hoshyar AH, Shabane S, Shahidsales S. Female genital tract  
177 tuberculosis presenting as ovarian cancer. *J Res Med Sci.* 2014;19(2):184-9.
- 178 7. Namavar Jahromi B, Parsanezhad ME, Ghane-Shirazi R. Female genital tuberculosis and  
179 infertility. *Int J Gynaecol Obstet.* 2001;75(3):269-72.
- 180 8. Attah EB. Human Pathology, a complete text for Africa. In: B.Attah E, editor. *Human Pathology, a  
181 complete text for Africa.* 2. 1st ed. Ibadan: Ibadan University Press; 2002. p. 179-90.
- 182 9. Grace GA, Devaleenal DB, Natrajan M. Genital tuberculosis in females. *Indian J Med Res.*  
183 2017;145(4):425-36.
- 184 10. Aliyu MH, Aliyu SH, Salihu HM. Female genital tuberculosis: a global review. *Int J Fertil Womens  
185 Med.* 2004;49(3):123-36.
- 186 11. Sachan R, Patel ML, Gupta P, Verma AK. Genital tuberculosis with variable presentation: a series  
187 of three cases. *BMJ Case Rep.* 2012;2012.
- 188 12. Qureshi RN, Samad S, Hamid R, Lakha SF. Female genital tuberculosis revisited. *J Pak Med Assoc.*  
189 2001;51(1):16-8.
- 190 13. Djuwantono T, Permadi W, Septiani L, Faried A, Halim D, Parwati I. Female genital tuberculosis  
191 and infertility: serial cases report in Bandung, Indonesia and literature review. *BMC Res Notes.*  
192 2017;10(1):683.
- 193 14. Desai R, Kumar S, Brindini U. Female genital tuberculosis: a clinicopathological study.  
194 *International Journal of Reproduction, Contraception, Obstetrics and Gynecology.* 2016:2780-3.
- 195 15. Neonakis IK, Spandidos DA, Petinaki E. Female genital tuberculosis: a review. *Scand J Infect Dis.*  
196 2011;43(8):564-72.
- 197 16. Chavhan GB, Hira P, Rathod K, Zacharia TT, Chawla A, Badhe P, et al. Female genital tuberculosis:  
198 hysterosalpingographic appearances. *Br J Radiol.* 2004;77(914):164-9.
- 199 17. Tripathy SN, Tripathy SN. Infertility and pregnancy outcome in female genital tuberculosis. *Int J  
200 Gynaecol Obstet.* 2002;76(2):159-63.
- 201 18. Kulshrestha V, Kriplani A, Agarwal N, Singh UB, Rana T. Genital tuberculosis among infertile  
202 women and fertility outcome after antitubercular therapy. *Int J Gynaecol Obstet.*  
203 2011;113(3):229-34.
- 204 19. John M, Kukkady ZA. Genital tuberculosis and infertility. *Int J Gynaecol Obstet.* 1999;64(2):193-4.
- 205 20. A ML. Genital Tuberculosis in Female Infertility: An Enigma. *J Minim Invasive Gynecol.*  
206 2015;22(6S):S14.
- 207 21. Gupta N, Sharma JB, Mittal S, Singh N, Misra R, Kukreja M. Genital tuberculosis in Indian  
208 infertility patients. *Int J Gynaecol Obstet.* 2007;97(2):135-8.
- 209 22. Umoh A.V. GMA, . Genital tuberculosis with secondary infertility - a case report of successful  
210 treatment and subsequent livebirth in Uyo, Nigeria *J Med Med Sci* 2011 2((5) ):3839-42.
- 211 23. Sharma JB, Roy KK, Pushparaj M, Gupta N, Jain SK, Malhotra N, et al. Genital tuberculosis: an  
212 important cause of Asherman's syndrome in India. *Arch Gynecol Obstet.* 2008;277(1):37-41.
- 213 24. Parikh FR, Nadkarni SG, Kamat SA, Naik N, Soonawala SB, Parikh RM. Genital tuberculosis--a  
214 major pelvic factor causing infertility in Indian women. *Fertil Steril.* 1997;67(3):497-500.
- 215 25. Arpitha V, Savitha C, Nagarathnamma R. Diagnosis of genital tuberculosis: correlation between  
216 polymerase chain reaction positivity and laparoscopic findings. *International Journal of  
217 Reproduction, Contraception, Obstetrics and Gynecology.* 2016:3425-32.
- 218 26. Baum SE, Dooley DP, Wright J, Kost ER, Storey DF. Diagnosis of culture-negative female genital  
219 tract tuberculosis with peritoneal involvement by polymerase chain reaction. *J Reprod Med.*  
220 2001;46(10):929-32.

- 221 27. Mirlina ED, Lantsov VA, Semenovskii AV, Oleinik AN, Popova SS, Manicheva OA, et al. [Diagnostic  
222 values of polymerase chain reaction test in females with genital tuberculosis]. *Probl Tuberk.*  
223 1998(1):46-8.
- 224 28. Jaiprakash P, Pai K, Rao L. Diagnosis of tuberculous cervicitis by Papanicolaou-stained smear.  
225 *Ann Saudi Med.* 2013;33(1):76-8.
- 226 29. Ilmer M, Bergauer F, Friese K, Mylonas I. Genital tuberculosis as the cause of tuboovarian  
227 abscess in an immunosuppressed patient. *Infect Dis Obstet Gynecol.* 2009;2009:745060.
- 228 30. Giannacopoulos K, Hatzidaki EG, Papanicolaou NC, Relakis KJ, Kokori HG, Giannacopoulou CC.  
229 Genital tuberculosis in a HIV infected woman: a case report. *Eur J Obstet Gynecol Reprod Biol.*  
230 1998;80(2):227-9.
- 231 31. Patacchiola F, Di Stefano L, Palermo P, Di Berardino C, Coppola G, Mascaretti G. Genital  
232 tuberculosis in a menopausal woman. A case report. *Minerva Ginecol.* 2002;54(3):287-91.
- 233 32. Zhuchenko OG, Stepanova TV, Gulua IR. [Genital tuberculosis and surgical treatment of it]. *Probl*  
234 *Tuberk.* 2001(9):53-6.
- 235 33. Jolobe O. Genitourinary tuberculosis, CA-125 and tuberculin anergy in disseminated  
236 tuberculosis. *QJM.* 2015;108(12):993.
- 237 34. Meden H, Fattahi-Meibodi A. CA 125 in benign gynecological conditions. *Int J Biol Markers.*  
238 1998;13(4):231-7.

239

240