

Biochemical and molecular studies on the role of rosemary extract in reducing liver and kidney toxicity due to Vepesid in male rats

ABSTRACT

Aims: Vepesid is chemotherapeutic drugs that inhibit topoisomerase II activity and long been used for treatment of human malignancies, where it is a semi-synthetic compound derived from the plant podophyllum pelltatum. The current study was designed to investigate the possible protective effect of rosemary extract against Vepesid -induced changes in liver and kidney functions, and DNA damage in rats.

Materials and Methods: A total of 50 male Wistar albino rats were divided randomly into four groups (1st group was control; 2nd group was treated with rosemary, 3rd group was received Vepesid, and 4th & 5th groups was co- and post treated groups respectively).

Results: The administration of Vepesid revealed a significant increase in serum ALT, AST, ALP, creatinine, urea, potassium ions, chloride ions, and DNA damage. In contrast; a significant decrease in albumen, total proteins, sodium ions, and calcium ions were when compared with control group. This increased in ALT, AST, ALP, creatinine, urea, potassium ions, chloride ions, and DNA damage was reduced after administration of rosemary when co-treated with Vepesid (G4), or post-treated after Vepesid (G5) for four weeks with lowest damage in G4. Also; this decreased in albumen, total proteins, sodium ions, and calcium ions was increased after administration of rosemary when co-treated with Vepesid (G4), or post-treated after Vepesid (G5) for four weeks with lowest damage in G4.

Conclusion: it could be concluded that rosemary has a promising role and it worth to be considered as a natural substance for protective the liver and kidney toxicity induced by Vepesid chemotherapy.

Key words: Chemotherapy; Vepesid; Rosemary; Liver; Kidney; Rat.

1. INTRODUCTION

Today, there are many different kinds of chemotherapy that used for cancer treatments. It is therefore important to search for therapies which can reduce the side effects of anticancer treatments without altering their efficacy or increasing toxicity or damage in target organs [1-8]. Vepesid or VP-16 is the trade name for etoposide. Etopophos and toposar or etoposide phosphate are other names for Vepesid. In some cases, health care professionals may use the trade name VP-16 or other names Vepesid or etopophos or toposar or etoposide phosphate when referring to the generic drug name etoposide. Vepesid is chemotherapeutic drugs that inhibit topoisomerase II activity and long been used for treatment of human malignancies, where it is a semi-synthetic compound derived from the plant podophyllum pelltatum [9,10].

Vepesid is commonly used alone or with another anticancer agent for the treatment of Hodgkin's lymphoma and AID's and sexual organ cancers as testicular, ovarian, uterine, bladder and prostate or for the treatment of other organs as lung and stomach cancer [10]. Although Vepesid is effective in

Comment [U1]: Wistar

Comment [U2]: Vepesid

Comment [U3]: Vepesid

Comment [U4]: Keywords are usually arranged in alphabetical

28 the treatment of different types of cancers, it causes the death of normal proliferating cells, including
29 male germ cells [9].
30 Many plant extracts and their products have been shown to have significant antioxidant activity which
31 may be an important property of medicinal plants associated with the treatment of several ill-fated
32 diseases including liver toxicity [11-19].
33 Rosemary (*Rosemarinus officinalis*) is one of household herbs that contains a number of
34 phytochemicals, including rosmarinic acid, camphor, caffeic acid, ursolic acid, betulinic acid, and the
35 antioxidants carnosic acid and it used in traditional medicine to treat a variety of disorders [20-22].
36 Extracts of rosemary leaves contains flavonoids and phenols and it possess a variety of bioactivities in
37 vitro including anti-tumor, antioxidant, antibacterial, antinociceptive, antidiabetic, antithrombotic,
38 antiulcerogenic, antidiuretic and anti-inflammatory agents [10,22]. Therefore; the present study was
39 conducted to examine the possible modifying effects of rosemary aqueous extract against the changes
40 in the liver and kidney function and DNA damage, induced by Vepesid in male rats.

41

42 2. MATERIAL AND METHODS

43

44 2.1. Animals

45 The experiments were performed on 50 male rats weighing 130±10g and of 10 week's age. The rats
46 were kept in our Faculty animal house for one week before the experimental work and maintained on
47 a standard rodent diet and water available *ad libitum*. After one weeks of acclimation, rats were
48 equally divided into four groups. [1]

49 **How about extraction of Rosemary**

50 2.2. Experimental groups

51 Rats were equally divided into four groups.

52 1st group: Control group included rats received no treatment.

53 2nd group: Rosemary group included rats received by oral gavages rosemary extract at a dose of (220
54 mg/kg b.w. /twice weekly) for six weeks [21].

55 3rd group: Vepesid group included rats that injected intraperitoneally with Vepesid (1 mg /kg
56 B.W/day) for six weeks [10].

57 4th group: Co-treated group included rats that injected by Vepesid (1 mg/kg B.W. /day) for six weeks
58 and received rosemary (220 mg /kg b.w. /twice weekly) orally for the same six weeks.

59 4th group: Post treated group included rats that injected by Vepesid (1 mg/kg B.W. /day) for six weeks
60 and then received rosemary (220 mg /kg b.w. /twice weekly) orally for another six weeks.

61 At the end of the experimental period, rats were fasted overnight; euthanized with intraperitoneal
62 injection with sodium pentobarbital and subjected to a complete necropsy. Blood samples were
63 individually collected from the inferior vena cava of each rat in non-heparinized glass tubes for
64 estimation of liver and kidney functions biomarkers [23]. Blood samples were incubated at room
65 temperature for 10 minutes and left to clot then centrifuged at 3000 r.p.m for 15 min and the serum
66 were collected, serum was separated and kept in clean stopper plastic vial at -80°C until the analysis
67 of serum parameters.

68

69 2.3 Liver function Biomarker:

70 Alanine transaminase (ALT) and aspartate transaminase (AST) activities in serum were assayed by
71 using commercial kit that was supplied by Humann (Germany) according to the method of Tousson et
72 al. [24] and Bolkinny et al. [25] respectively while alkaline phosphatase (ALP) was estimated in the rat
73 serum according to El-Moghazy et al. [11]. Serum albumin was estimated according to Basuony et al.
74 [6] while serum total proteins level was estimated according to Tousson et al. [26].

75

76 2.4 Electrolytes and kidney functions Biomarker:

77 Serum urea and creatinine were determined in the rat sera according to Salama et al. [27] and Eldaim
78 et al. [28] respectively. To measure the levels of serum electrolytes (Potassium, sodium, calcium and
79 chloride ion) by using commercial kits (Sensa core electrolyte, India) according to El Atrash et al.
80 [29].

Comment [U5]: No ethical clearance

Comment [U6]: How much rosemary and what solvent is used for extraction. What extraction method is used

81
82
83
84
85
86
87
88
89
90
91
92
93
94
95
96
97
98
99
100
101
102
103
104
105
106
107
108
109
110
111
112
113
114
115
116
117
118
119
120
121
122
123
124
125

2.5 Comet assay

One gram of crushed kidney tissue was transferred to 1 mL of ice-cold phosphate-buffered saline (PBS) and the assay was performed according to Eldaim et al. [28], for visualization of DNA damage, observations were carried out on GelRed-stained DNA using a 40× objective on a fluorescent microscope. Comet 5 image analysis software developed by Kinetic Imaging, Ltd. (Liverpool, UK) linked to a CCD camera was used to assess the quantitative and qualitative extent of DNA damage in the cells by measuring the length of DNA migration and the percentage of migrated DNA. Finally, the program calculates tail moment. Generally, 50–100 randomly selected cells are analysed per sample.

2.6. Statistical Analysis

Data were expressed as mean values ± SE and statistical analysis was performed using one way ANOVA to assess significant differences among treatment groups. The criterion for statistical significance was set at $p < 0.01$ for the biochemical data. All statistical analyses were performed using SPSS statistical version 16 software package (SPSS® Inc., USA).

3. RESULTS

3.1. Serum markers of liver damage

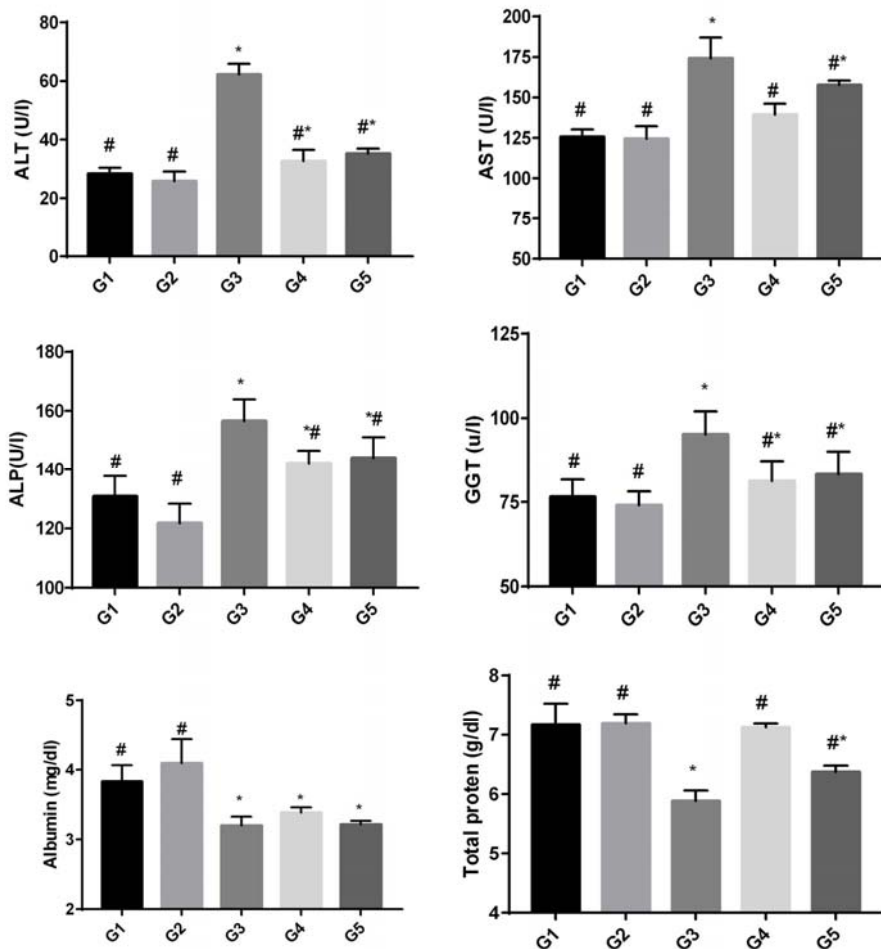
Data presented in Figure (1) showed that serum ALT, AST, ALP and total bilirubin levels were significantly ($P < 0.05$) increase in treated rats with Vepesid as compared to control group. In contrast; a significant ($P < 0.05$) decrease in total protein and albumin levels in treated rats with Vepesid as compared to control group (Figure 1). Treatment of rats with Vepesid and rosemary (as in G4&G5) revealed a significant ($P < 0.05$) decrease in ALT, AST, ALP and total bilirubin levels and a significant ($P < 0.05$) increase in total protein and albumin levels when compared with treated rats with Vepesid (Figure 1). Also; with lowest damage in G4

3.2. Serum markers of kidney damage

Data presented in Figure (2) showed that serum creatinine, urea, potassium and chloride ions levels were significantly ($P < 0.05$) increase in treated rats with Vepesid as compared to control group. In contrast; a significant ($P < 0.05$) decrease in serum sodium and calcium ions levels in treated rats with Vepesid as compared to control group (Figure 2). Treatment of rats with Vepesid and rosemary (as in G4&G5) revealed a significant ($P < 0.05$) decrease in creatinine, urea, potassium and chloride ions levels and a significant ($P < 0.05$) increase in sodium and calcium ions levels when compared with treated rats with Vepesid (Figure 1).

3.3. DNA damage in liver tissues

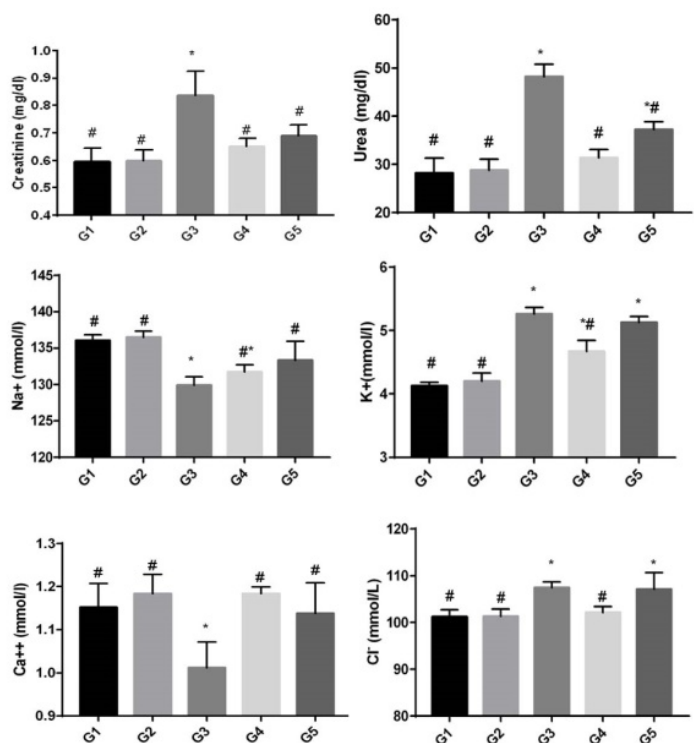
A comet assay was performed to assess DNA damage in liver of rats after treatment by rosemary and/or Vepesid as compared to normal control. The results of comet assay were shown in Figures (3) and Tables (1). Administration of Vepesid (G3) led to significant increase in liver DNA damage ($P < 0.05$) that was indicated by increase in tail length, tail DNA% and tail moment as compared to normal control (G1) and rosemary (G2) groups (Table 1 & Figure 3). This increased liver DNA damage was reduced after administration of rosemary when co-treated with Vepesid (G4), or post-treated after Vepesid (G5) for four weeks with lowest damage in G4. On the other hand, no significant difference in liver DNA damage (tail length) was observed between normal control (G1) and rosemary treated groups (G2).



126

127 **Figure 1:** Changes in serum ALT, AST, ALP, GGT, total protein and albumin levels in different
 128 groups under study. Data are expressed as mean \pm SE of 10 observations. *Significant difference from
 129 control group at $P < 0.05$. #Significant difference from Vepsid group at $P < 0.05$. Where G1, control
 130 group; G2, rosemary group; G3, Vepsid group; G4, co-treated Vepsid with rosemary group; G5, post-
 131 treated Vepsid with rosemary group.

132



133

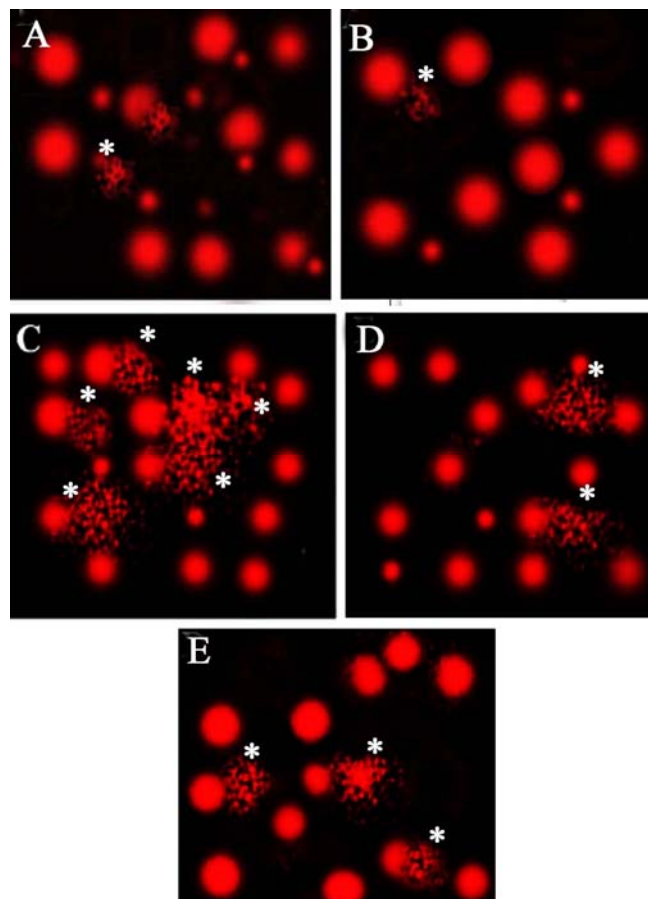
134 **Figure 2:** Changes in serum kidney functions (creatinine and urea) and electrolytes (sodium,
 135 potassium, calcium and chloride ions) levels in different groups under study. Data are expressed as
 136 mean \pm SE of 10 observations. *Significant difference from control group at $P < 0.05$. #Significant
 137 difference from Vepsid group at $P < 0.05$. Where G1, control group; G2, rosemary group; G3, Vepsid
 138 group; G4, co-treated Vepsid with rosemary group; G5, post-treated Vepsid with rosemary group.

139 **Table 1:** Comet assay parameters obtained by image analysis in liver cells of all groups after
 140 prevention experiment.

Group	Tailed %	Untailed %	Tails length μm	Tail DNA%	Tail moment
G1	4	96	1.79 \pm 0.35 ^d	1.68	3.04
G2	1.5	98.5	1.34 \pm 0.10 ^d	1.39	1.86
G3	19	81	6.55 \pm 0.34 ^a	5.05	33.08
G4	9	91	3.73 \pm 0.13 ^c	3.02	11.26
G5	12	88	4.62 \pm 0.21 ^b	3.70	17.09

141 Different superscript letters in the same column of tail length showed significance difference at $P <$
 142 0.05. Where G1, control group; G2, rosemary group; G3, Vepsid group; G4, co-treated Vepsid with
 143 rosemary group; G5, post-treated Vepsid with rosemary group.

144



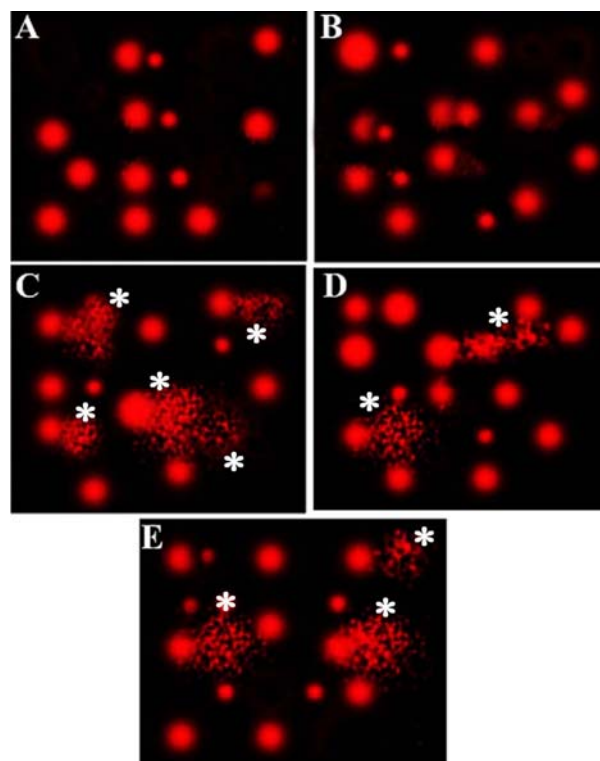
146

147 **Figure 3:** Photomicrographs representation of DNA damage in liver tissues, using comet assay, in
 148 normal control group (A), rosemary group (B), Vepsid group (C), co-treated Vepsid with rosemary
 149 group (D), and post-treated Vepsid with rosemary group (E).

150

151 3.4. DNA damage in kidney tissues

152 A comet assay was performed to assess DNA damage in kidney of rats after treatment by rosemary
 153 and/or Vepsid as compared to normal control. The results of comet assay were shown in Figures (4)
 154 and Tables (2). Administration of Vepsid (G3) led to significant increase in kidney DNA damage ($P <$
 155 0.05) that was indicated by increase in tail length, tail DNA% and tail moment as compared to normal
 156 control (G1) and rosemary (G2) groups (Table 2 & Figure 4). This increased kidney DNA damage
 157 was reduced after administration of rosemary when co-treated with Vepsid (G4), or post-treated after
 158 Vepsid (G5) for four weeks with lowest damage in G4. On the other hand, no significant difference
 159 in kidney DNA damage (tail length) was observed between normal control (G1) and rosemary treated
 160 groups (G2).



162

163 **Figure 4:** Photomicrographs representation of DNA damage in kidney tissues, using comet assay, in
 164 normal control group (A), rosemary control group (B), positive control group (C), co-treated **Vepsid**
 165 with rosemary group (D), and post treated **Vepsid** with rosemary group (E).

166 **Table 2:** Comet assay parameters obtained by image analysis in cells of all groups after treatment
 167 experiment.

Group	Tailed %	Untailed %	Tails length μm	Tail DNA%	Tail moment
G1	1.5	98.5	1.36 ± 0.11^d	1.46	1.99
G2	3	97	1.48 ± 0.12^d	1.60	2.37
G3	16	84	5.70 ± 0.35^a	4.71	26.85
G4	7	93	3.11 ± 0.17^c	2.28	7.09
G5	11	89	4.47 ± 0.12^b	3.51	15.69

168

169 Different superscript letters in the same column of tail length showed significance difference at $P <$
 170 0.05. Where G1, control group; G2, rosemary group; G3, **Vepsid** group; G4, co-treated **Vepsid** with
 171 rosemary group; G5, post-treated **Vepsid** with rosemary group.

172 **4. DISCUSSION**

Comment [U7]: The title should not be separated from the contents, move it to the next page.

173 Chemotherapy involves the use of chemical agents to stop the growth and eliminate cancer cells even
174 at distant sites from the origin of primary tumor [6]. However, it does not distinguish between a
175 cancer and normal cells, and eliminates not only the fast-growing cancer cells but also other fast-
176 growing cells in the body, including, hair and blood cells. The current study aimed to study the
177 protective and ameliorating effects of rosemary extract against liver toxicity induced by Vepsid in
178 male albino rats.

179 Chemotherapy-induced hepatotoxicity is a common cause of abnormal liver function test in patients,
180 this hepatotoxicity are usually begins with vague clinical symptoms such as fatigue, anorexia, nausea,
181 dark urine, right upper quadrant discomfort and jaundice. In the current study; a significant increase in
182 serum ALT, AST, ALP and a significant decrease albumen and total proteins indicated the liver
183 toxicity were detected after the treatments of rats with Vepsid as compared with control. This result is
184 in harmony with Abouzeinab [30]; Nasr [31]; Abdel-Wahhab et al. [32] and Basuony et al. [6] who
185 reported that, Cisplatin administration induced an increase in ALT, AST, ALP and decrease albumen
186 and total proteins. Also; this current result is in harmony with Tousson et al. [3,4] who reported that;
187 methotrexate-induced hepatic and renal toxicity in male rats and the increased in liver function
188 associated with free radicals trigger cell damage through binding to cellular macromolecules. Similar
189 findings were reported by Juma [33] and McDonald et al. [34] who reported that; cyclophosphamide -
190 Induced hepatotoxicity in human liver. Elevated levels of serum ALT and AST enzymes are
191 indicative of cellular leakage and loss of functional integrity of cell membranes in the liver [12,24].
192 The estimation of these enzymes in the serum is a useful quantitative marker for the extent and type of
193 hepatocellular damage [7,8,35].

194 Urea and creatinine are nitrogenous end products of metabolism. Urea is the primary metabolite
195 derived from dietary protein and tissue protein turnover [27,36,37]. Creatinine is the product of
196 muscle creatine catabolism. Both are relatively small molecules (60 and 113 daltons, respectively)
197 that distribute throughout total body water. The rationale for the use of creatinine or urea
198 measurement to assess renal function is that plasma/serum levels of both reflect glomerular filtration
199 rate (GFR), the parameter that defines kidney function for the clinician. Irrespective of its cause,
200 kidney disease is associated with decrease in GFR, and the severity of kidney disease correlates
201 closely but inversely with GFR [38].

202 Chemotherapy-induced renal tototoxicity is a common cause of abnormal kidney function test in
203 patients and in animal models. Renal injury may follow treatment with anticancer drugs and lead to
204 glomerular, tubular dysfunctions, or any combination of these [39]. Nephrotoxicity is an unusual side
205 effect of chemotherapy in general. Most chemotherapy drugs target pathways that are essential to
206 dividing cells. In the current study; serum creatinine, urea, potassium and chloride ions levels were
207 significantly ($P<0.05$) increase in treated rats with Vepsid as compared to control group. In contrast;
208 a significant ($P<0.05$) decrease in serum sodium and calcium ions levels were detected in treated rats
209 with Vepsid as compared to control group. Mechanisms of anticancer drug-induced renal disorders
210 generally include a varying degree of prerenal hypoperfusion, intrinsic renal damage, renal tubular
211 obstruction, and damage to the microvascular structure of the kidneys [40]. Our result is agree with
212 Tousson et al. [1] who find that MTX increased urea and creatinine activities which induced renal
213 toxicity. Our result is agreed with Basuony et al. [6] who reported that; Cisplatin induced renal
214 toxicity in rats. On the other hand, our results are disagreement with Cetiner et al. [41]. Our result is
215 agreed with Beyer et al. [42] who reported that; High-dose carboplatin, etoposide and ifosfamide
216 induced renal toxicity in human. Also; our result is agreed with Al-Ameri [43] who reported
217 Etoposide induced kidney toxicity, electrolytes changes and injury. Chemotherapy-induced
218 nephrotoxicity is a major cause of morbidity and mortality among cancer patients. Therefore,
219 assessing baseline renal function before initiation of therapy and during therapy, adjusting drug
220 dosages, avoiding nephrotoxic drug combinations, and correcting the extracellular fluid volume
221 depletion is essential in the cancer patients [44].

222 Treatment of rats with Vepsid and rosemary revealed a significant decrease in creatinine, urea,
223 potassium and chloride ions levels and a significant ($P<0.05$) increase in sodium and calcium ions

224 levels when compared with treated rats with Vepesid indicated that rosemary has renal protective
225 against chemotherapy. The topoisomerase II inhibitor etoposide is an antineoplastic drug that has been
226 widely used to couple DNA damage to apoptosis [45]. Topoisomerase II is a nuclear enzyme that
227 functions during both DNA replication and transcription [46]. Topoisomerase II prevents “knots”
228 from forming in DNA by allowing the passage of an intact segment of the helical DNA through a
229 transient double strand break [47]. Topoisomerase II inhibitors such as etoposide stabilize the
230 complex formed by topoisomerase II and the 5'-cleaved ends of the DNA, thus forming stable
231 (nonrepairable) protein-linked DNA double strand breaks [47]. Cells are apparently able to recognize
232 such DNA damage and, in turn, to eliminate the injured cells by apoptosis. In the current study,
233 treatment of rats with Vepesid led to significant increase in liver and kidney DNA damage ($P < 0.05$)
234 that was indicated by increase in tail length, tail DNA% and tail moment as compared to normal
235 control and rosemary groups. This increased kidney DNA damage was reduced after administration of
236 rosemary when co-treated with Vepesid (G4), or post-treated after Vepesid (G5) for four weeks with
237 lowest damage in G4. Our results agree with Tousson et al. [10] who reported that; Etoposide
238 induced DNA damage in testicular tissues.
239

240 5. CONCLUSION

241 Our recommendation is Etoposide treatments induced changes in liver and kidney functions and DNA
242 damage. Physicians should be aware of Etoposide a differential diagnosis for hepatic and renal with
243 an unknown etiology. Rosemary has a promising role and it worth to be considered as a natural
244 substance for protective the liver and kidney toxicity induced by Vepesid chemotherapy.
245

246 Conflict of interests

247 The authors declare no conflict of interest.
248
249

250 REFERENCES

- 251 1 Tousson E, Atteya Z, El-Atrash E, Jeweely OI. Abrogation by Ginkgo Byloba leaf
252 extract on hepatic and renal toxicity induced by methotrexate in rats. J Cancer
253 Res Treat. 2014;2(3):44-51.
- 254 2 Tousson E, Hafez E, Zaki S, Gad A. P53, Bcl-2 and CD68 expression in response
255 to amethopterin-induced lung injury and ameliorating role of l-carnitine.
256 Biomedicine & Pharmacotherapy. 2014;68(5):631-9.
- 257 3 Tousson E, Hegazy M, Hafez E, Ahmed EA. The effect of L-carnitine on
258 amethopterin-induced toxicity in rat large intestine. J Cancer Res Treat.
259 2014;2(3):55-63.
- 260 4 Tousson E, Zaki ZT, Abu-Shaeir WA, Hassan H. Methotrexate-induced hepatic
261 and renal toxicity: role of L-carnitine in treatment. Biomed Biotechnol.
262 2014;2(4):85-92.
263

- 264 5 Tousson E, Hafez E, Zaki S, Gad A. The cardioprotective effects of L-carnitine on
265 rat cardiac injury, apoptosis, and oxidative stress caused by amethopterin.
266 *Environmental Science and Pollution Research*. 2016;23(20):20600-8.
- 267 6 Basuony M, Hafez E, Tousson E, Massoud A, Elsomkhraty S, Eldakamawy S.
268 Beneficial role of Panax ginseng root aqueous extract against Cisplatin induced
269 blood toxicity in rats. *Am J Biol Chem*. 2015;3(1):1-7.
- 270 7 Al-Rasheed NM, El-Masry TA, Tousson E, Hassan HM, Al-Ghadeer A. Hepatic
271 protective effect of grape seed proanthocyanidin extract against Gleevec-
272 induced apoptosis, liver Injury and Ki67 alterations in rats. *Brazilian Journal of*
273 *Pharmaceutical Sciences*. 2018;54(2). e17391
- 274 8 Al-Rasheed NM, El-Masry TA, Tousson E, Hassan HM, Al-Ghadeer A. Protective
275 Potential of Grape Seed Proanthocyanidins Extract against Glivec (Imatinib
276 Mesylate) Induced Liver Toxicity and Oxidative Stress in Male Rats. *Annual*
277 *Research & Review in Biology*, 2017; 20 (6): 1-9.
- 278 9 Shin, H.J., Kwon, H.K., Lee, J.H., Anwar, M.A., Choi, S. (2016). Etoposide
279 induced cytotoxicity mediated by ROS and ERK in human kidney proximal
280 tubule cells. *Scientific reports*, 6:1-13.
- 281 10 Tousson E, Bayomy MF, Ahmed AA. Rosemary extract modulates fertility
282 potential, DNA fragmentation, injury, KI67 and P53 alterations induced by
283 etoposide in rat testes. *Biomedicine & Pharmacotherapy*. 2018;98:769-74.
- 284 11 El-Moghazy M, Zedan NS, El-Attrsh AM, El-Gogary M, Tousson E. The possible
285 effect of diets containing fish oil (omega-3) on hematological, biochemical and
286 histopathological alterations of rabbit liver and kidney. *Biomedicine &*
287 *Preventive Nutrition*. 2014;4(3):371-7.
- 288 12 Tousson E, Alghabban AJ, Harga HA. Thyroidectomy induced hepatic toxicity
289 and possible amelioration by Ginkgo biloba leaf extract. *Biomedicine &*
290 *Preventive Nutrition*. 2014;4(3):391-7.
- 291 13 Saggu S, Sakeran MI, Zidan N, Tousson E, Mohan A, Rehman H. Ameliorating
292 effect of chicory (*Chichorium intybus* L.) fruit extract against 4-tert-

- 293 octylphenol induced liver injury and oxidative stress in male rats. Food and
294 chemical toxicology. 2014;72:138-146.
- 295 13 Salama AF, Tousson E, Elfetoh EM, Elhaak M, Elawni M. Effect of Egyptian
296 plant *Silybum marianum* on the kidney during the treatment of liver fibrosis in
297 female albino rats induced by alcohol in comparison to the medical silymarin
298 from China. international journal of current microbiology and applied sciences,
299 2015;4(3):557-70.
- 300 15 Elmasry TA, Al-Shaalan NH, Tousson E, El-Morshedy K, Al-Ghadeer A. Star
301 anise extracts modulation of reproductive parameters, fertility potential and
302 DNA fragmentation induced by growth promoter Equigan in rat testes.
303 Brazilian Journal of Pharmaceutical Sciences. 2018;54(1).
- 304 16 Abd Eldaim MA, Tousson E, El Sayed IE, Awd WM. Ameliorative effects of
305 *Saussurea lappa* root aqueous extract against Ethephon-induced reproductive
306 toxicity in male rats. Environmental toxicology. 2019;34(2):150-9.
- 307 17 Oyouni AA, Saggi S, Tousson E, Mohan A, Farasani A. Mitochondrial
308 nephrotoxicity induced by tacrolimus (FK-506) and modulatory effects of
309 *Bacopa monnieri* (Farafakh) of Tabuk Region. Pharmacognosy Research.
310 2019;11(1):20.
- 311 18 Oyouni AA, Saggi S, Tousson E, Rehman H. Immunosuppressant drug
312 tacrolimus induced mitochondrial nephrotoxicity, modified PCNA and Bcl-2
313 expression attenuated by *Ocimum basilicum* L. in CD1 mice. Toxicology
314 reports. 2018;5:687-94.
- 315 19 Aldubayan MA, Elgharabawy RM, Ahmed AS, Tousson E. Antineoplastic
316 activity and curative role of Avenanthramides against the growth of Ehrlich
317 solid tumors in mice. Oxidative Medicine and Cellular Longevity. 2019;2019.
318 ID 5162687, 12 pages <https://doi.org/10.1155/2019/5162687>
- 319 20 Gad AS, EL-SALAM MH. The antioxidant properties of skim milk
320 supplemented with rosemary and green tea extracts in response to
321 pasteurisation, homogenisation and the addition of salts. International journal
322 of dairy technology. 2010;63(3):349-55.

- 323 21 Akela MA, El Atrash AM, El Kilany MI, Tousson E. Qualitative and quantitative
324 characterization of biologically active compounds of Rosemary (*Rosmarinus*
325 *officinalis*) Leaf Extract. *Journal of Advanced Trends in Basic and Applied*
326 *Science*, 2018, 2(1):59-64.
- 327 22 Habtemariam, S. The therapeutic potential of rosemary (*Rosmarinus officinalis*)
328 diterpenes for Alzheimer's disease. *Evidence-Based Complementary and*
329 *Alternative Medicine*, 2016; 1-14.
- 330 23 Tousson E, El-Moghazy M, Massoud A, El-Atrash A, Sweef O, Akel A.
331 Physiological and biochemical changes after boldenone injection in adult
332 rabbits. *Toxicology and industrial health*. 2016;32(1):177-82.
- 333 24 Tousson E, Keshta AT, Hussein Y, Fekry RM, Abo-Ghaneima WK. Renal
334 Protective Effect of Ginkgo biloba and L-carnitine Extracts against
335 Pentylentetrazol Induced Toxicity, Oxidative Stress, Injury and Proliferation
336 Alternation in Epileptic Rats. *Annual Research & Review in Biology*. 2019;
337 28:1-3.
- 338 25 Bolkin Y, Tousson E, El-Atrash A, Akela M, Farg E. (2019) Costus Root Extract
339 Alleviates Blood Biochemical Derangements of Experimentally-Induced
340 Hypo-and Hyperthyroidism in Mice. *Annual Research & Review in Biology*.
341 2019; 31(5):1-0.
- 342 26 Tousson E, El-Moghazy M, El-Atrash E. The possible effect of diets containing
343 *Nigella sativa* and *Thymus vulgaris* on blood parameters and some organs
344 structure in rabbit. *Toxicology and industrial health*. 2011;27(2):107-16.
- 345 27 Salama AF, Kasem SM, Tousson E, Elsisy MK. Protective role of L-carnitine and
346 vitamin E on the kidney of atherosclerotic rats. *Biomedicine & Aging*
347 *Pathology*. 2012;2(4):212-5.
- 348 28 Eldaim MA, Tousson E, El Sayed IE, El AE, Elsharkawy HN. Grape seeds
349 proanthocyanidin extract ameliorates Ehrlich solid tumor induced renal tissue
350 and DNA damage in mice. *Biomedicine & Pharmacotherapy*.
351 2019;115:108908.

- 352 29 El Atrash A, Tousson E, Gad A, Allam S. Hematological and Biochemical
353 Changes Caused by Antidepressants Amitriptyline Induced Cardiac Toxicity in
354 Male Rats. Asian Journal of Cardiology Research. 2019; 23:1-6.
- 355 30 Abouzeinab NS. Cytoprotective effect and antioxidant properties of silymarin on
356 cisplatin induced hepatotoxicity in rats: A biochemical and histochemical
357 study. International Journal of Cancer Research,2013; 9(1):9-23.
- 358 31 Nasr AY. Morphological, biochemical, histological, and ultrastructural protective
359 effects of misoprostol on cisplatin induced-hepatotoxicity in adult male
360 rats. Saudi Medical Journal, 2013;34(12):1237-1247.
- 361 32 Abdel-Wahhab MA, El-Denshary ES, El-Nekeety AA, Hassan NS, Abu-Salem
362 FM, Sarhan NA, Rihn BH. Impact of soy isoflavones on aflatoxin-induced
363 oxidative stress and hepatotoxicity in rats. General Health and Medical
364 Sciences, 2014;1(2): 9-14.
- 365 33 Juma FD. Effect of liver failure on the pharmacokinetics of
366 cyclophosphamide. European journal of clinical
367 pharmacology, 1984;26(5):591-593.
- 368 34 McDonald GB, Slattery JT, Bouvier ME, Ren S, Batchelder AL, Kalthorn TF,
369 Schoch HG, Anasetti C, Gooley T. Cyclophosphamide metabolism, liver
370 toxicity, and mortality following hematopoietic stem cell
371 transplantation. Blood, 2003;101(5):2043-2048.
- 372 35 Moustafa AH, Ali EM, Moselhey SS, Tousson E, El-Said KS. Effect of coriander
373 on thioacetamide-induced hepatotoxicity in rats. Toxicology and industrial
374 health. 2014;30(7):621-9.
- 375 36 Salama AF, Tousson E, Ibrahim W, Hussein WM. Biochemical and
376 histopathological studies of the PTU-induced hypothyroid rat kidney with
377 reference to the ameliorating role of folic acid. Toxicology and industrial
378 health. 2013;29(7):600-8.
- 379 37 Barakat LA, Tousson E, Ibrahim W, El-Hakeem AA. Role of propolis in
380 improving hepatic and renal damage in boldenone undecylenate in male rats.
381 American Journal of Biological Chemistry. 2015 29;3(1):8.

- 382 38 Alm-Eldeen A, Tousson E. Deterioration of glomerular endothelial surface layer
383 and the alteration in the renal function after a growth promoter boldenone
384 injection in rabbits. *Human & experimental toxicology*. 2012;31(5):465-72.
- 385 39 Denker B, Robles-Osorio ML, Sabath E. Recent advances in diagnosis and
386 treatment of acute kidney injury in patients with cancer. *Eur J Intern Med*.
387 2011;22: 348–54.
- 388 40 Salahudeen AK, Bonventre JV. Onconephrology: The latest frontier in the war
389 against kidney disease. *J Am Soc Nephrol*. 2013;24:26–30.
- 390 41 Cetiner M, Sener G, Sehirli AO, Eksioglu-Demiralp E, Ercan F, Sirvanci S, Gedik
391 N, Akpulat S, Tecimer T, Yegen BC. Taurine protects against methotrexate-
392 induced toxicity and inhibits leucocyte death. *Toxicol. Appl. Pharmacol*.
393 2005;209 (1): 39-50.
- 394 42 Beyer J, Rick O, Weinknecht S, Kingreen D, Lenz K, Siegert W. Nephrotoxicity
395 after high-dose carboplatin, etoposide and ifosfamide in germ-cell tumors:
396 incidence and implications for hematologic recovery and clinical outcome.
397 Bone marrow transplantation. 1997;20(10):813.
- 398 43 Al-Ameri AS. Prevention of Etoposide induced kidney toxicity, electrolytes,
399 injury and KI67 alternations in male rats treated with star anise. *Journal of*
400 *Bioscience and Applied Research*.2017;3(2-1):36-41.
- 401 44 Kleber M, Cybulla M, Bauchmüller K, Ihorst G, Koch B, Engelhardt M.
402 Monitoring of renal function in cancer patients: An ongoing challenge for
403 clinical practice. *Ann Oncol*. 2007;18:950–8
- 404 45 Mizumoto K, Rothman RJ, Farber JL. Programmed cell death (apoptosis) of
405 mouse fibroblasts is induced by the topoisomerase II inhibitor etoposide.
406 *Molecular pharmacology*. 1994;46(5):890-5.
- 407 46 Hande KR. Etoposide: four decades of development of a topoisomerase II
408 inhibitor. *European Journal of Cancer*. 1998;34(10):1514-21.
- 409 47 Burden DA, Osheroff N. Mechanism of action of eukaryotic topoisomerase II and
410 drugs targeted to the enzyme. *Biochimica et Biophysica Acta (BBA)-Gene*
411 *Structure and Expression*. 1998;1400(1-3):139-54.