

Histopathological changes in the kidney of the freshwater bronze featherback fish, *Notopterus notopterus* (Pallas, 1769) exposed to profenofos

Safiya Tazeen* and Kulkarni, R.S

DEPARTMENT OF P.G STUDIES AND RESEARCH IN ZOOLOGY
GULBARGA UNIVERSITY KALABURAGI 585106, INDIA

Abstract

The impact of profenofos, an organophosphate pesticide on the kidney of Indian freshwater teleost fish *Notopterus notopterus* was evaluated. The experimental group was exposed to sublethal concentration of profenofos at 7, 14 and 21 days. Histopathological changes due to the toxicity of pesticide in experimental and control kidney of the fish were observed by killing the animal every 7, 14 and 21 days. The kidneys were fixed in Bouin's solution, dehydrated in graded ethanol, infiltrated in xylene, sectioned at 4-6 μ and stained in haematoxylin and eosin. Haemorrhage, oedema, fragmented glomeruli and elongated kidney tubules in experimental fish, and no effect were however observed in control fishes. It is concluded that profenofos is significantly toxic to the fish.

Keywords: profenofos, histopathology, *Notopterus notopterus*, kidney, oedema

Introduction

Histopathology is a promising field for research in aquatic toxicology as it provides the real picture of the toxic of xenobiotics in vital functions of a living organism (Anees, 1976). Increasing productivity in the tropics and resulting human activities have caused serious damage to tropical ecosystems. The degradation of terrestrial and aquatic ecosystems due to xenobiotics is a major concern and is a direct result of the increased use of synthetic chemicals such as pesticides in productivity. Organophosphorus pesticides are widely used in tropical agriculture. The toxicity of these pesticides is based on inhibition of the enzyme acetylcholine esterase (AChE) and other enzymes like AAT and ALAT. The extent of histopathological damages induced in the fish and the number of cell damages in relation to the concentration of toxicants utilized in assessing the toxicity of pollutants. Couch (1975) stated that gill, liver, intestine and kidney of fishes are best-suited organs for histopathological studies.

Previous histopathological studies of fish exposed to pollutants revealed that fish organs are efficient indicators of water quality (Cardoso et al., 1996; Barlas 1999; Cengiz et al., 2001).

Profenofos is among the most toxic pesticide for aquatic life, especially to the fishes. Profenofos is in general use for pest control in pigeon pea, cotton and vegetables.

However, there has been little information on the histopathological impact of Profenofos on the fish kidney, Therefore, an attempt was made to determine the histopathological effects on the kidney in the fish *N. notopterus* exposed to Profenofos.

MATERIALS AND METHODS

Adult fishes were collected from the Bhima reservoir. The fish were transferred to the laboratory and they were acclimatized in glass aquaria 15 days prior to the experiment. Egg white and goat liver were given to the fish daily and water of the aquaria was renewed alternately to avoid contamination.

The fishes were divided into two groups in glass aquaria. Fish Ten fish were used for each group. Group I was exposed to commercial formulations of the pesticide. 96 hrs LC50 for profenofos was found as 0.7µg/L and for the present study 1/10th of the 96h LC50 value was taken as sublethal concentration. Group II was maintained in pesticide-free water to serve as a control.

Both the experimental and control fish were sacrificed every 7, 14 and 21 days. Immediately after decapitation the kidneys were removed and dropped into aqueous Bouin's fluid. After fixation for 24-30 hr, tissues were dehydrated through a graded series of ethanol, cleared in xylene and infiltrated in paraffin, 4-6µ thick sections were cut on a rotary microtome and stained in counterstains (Haematoxylin and Eosin). Pathological lesions were examined under a compound microscope.

Fig: 1: Control kidney

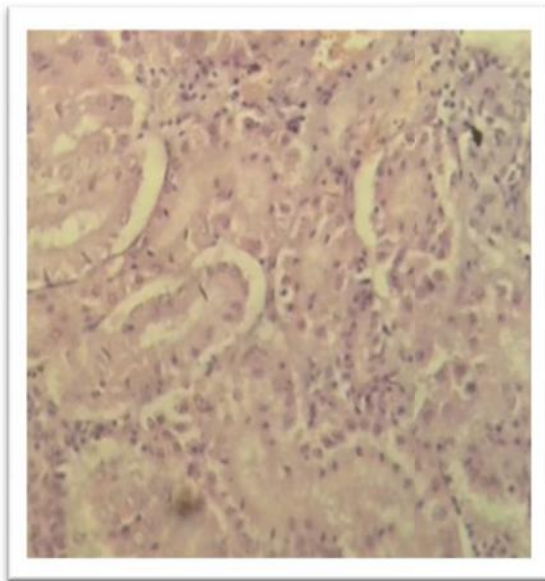


Fig: 2: Exposed for 7 days to sublethal concentration of profenofos

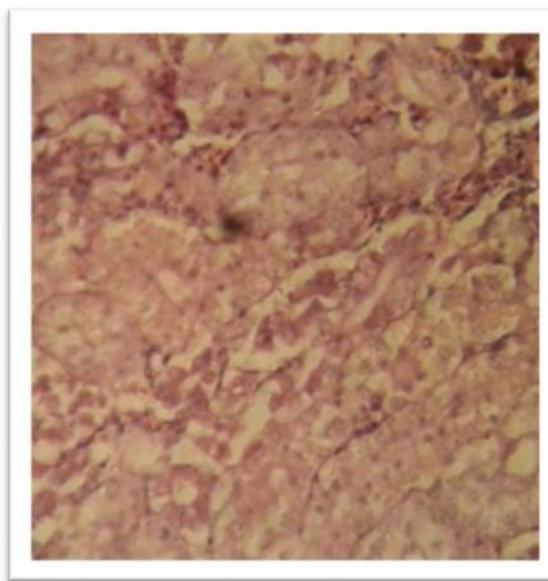


Fig: 3: kidney Exposed for 14 days to sublethal concentration of profenofos

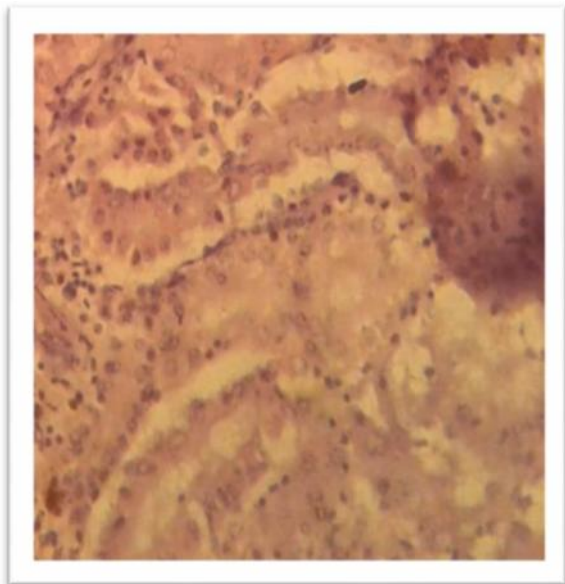
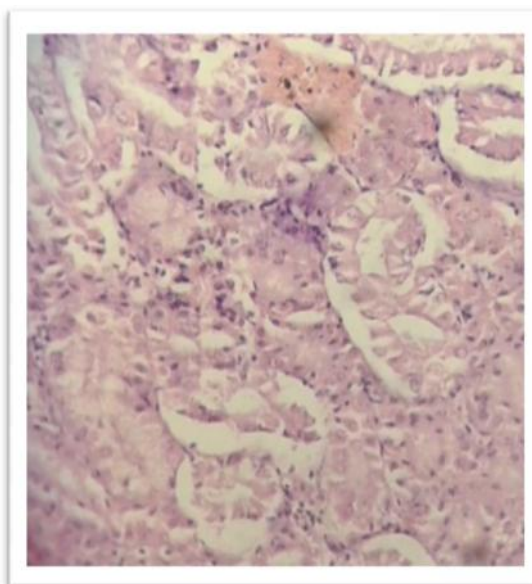


Fig: 4: kidney Exposed for 21 days to sublethal concentration of profenofos



Result and discussion

Renal excretion is one of the ways of eliminating toxicant molecules from the body. The kidney is an important organ of excretion and osmoregulation and it is highly susceptible to toxic substances of its high blood supply and it is considered as a major target organ for toxicity impact (Ananth and Mathivanan, 2014). Fish kidney receives the largest quantity of postbranchial blood, therefore renal lesions might be a good indicator of environmental pollution.

The histopathological changes were more evident in specimens exposed to Profenofos and were not observed in the control fish. After exposure, an excessive amount of mucus was observed over the body of live specimens. It has been reported that the stress caused by the variations in the environment and pathologic agents induced the proliferation of mucus cells and increased secretion (Richmonds and Dutta, 1989; Cardoso *et al.*, 1996).

In this study, fig:2 after 7 days of exposure to sublethal concentration of Profenofos, showing renal tubules with dilated lumen and fragmentation of glomeruli and haemorrhage, whereas fig:3, and 4 after 14 and 21 days exposed kidney showing necrosis, crumpled and pycnotic nucleus with haemorrhage with dislocation of epithelial cells and the inflammatory cells develop necrosis around the border of tissue changed the normal shape of kidney, whereas the section of control kidney tissues fig:1, exhibits an ordinary pattern with no abnormal changes in the cells .

These findings were similar to those of Yesudass Thangam (2014) in *Cirrhinus mrigala* exposed to nitrate and Anantha (2014) in *Ctenopharyngodon idella* exposed to arsenic trioxide.

According to Vinodhini and Narayanan, (2009) after exposure to heavy metal kidney exhibited the presence of macrophages with lipofusion granules accumulated in the affected cells to the fish *Cyprinus*

carpio. The present experimental study, exhibited the presence of vacuoles in the tubules and necrosis of kidney tubules in Profenofos (Curacron 50% EC) exposed fish, *N. notopterus*. A similar observation was made in the kidney of *Channa punctatus* exposed to heavy metal by Pandey *et al.*, (2008) and *Cirrhinus mrigala* exposed to nitrate by Yasudas Thangam (2014).

CONCLUSION

The impact of profenofos, an organophosphate pesticide on the kidney of Indian freshwater teleost fish *Notopterus notopterus* was evaluated. Haemorrhage, oedema, fragmented glomeruli and elongated kidney tubules in experimental fish, and no effect were however observed in control fishes. It is concluded that profenofos is significantly toxic to the fish. The present study indicated that exposure to sublethal concentration of Profenofos (Curacron 50% EC) caused histological alterations in the kidney of the freshwater fish *N. notopterus*.

REFERENCES

- Anantha S.** Studies on the impact of arsenic trioxide on certain aspects in selected tissues of freshwater fish *Ctenopharyngodon idella*, Ph. D. thesis, Annamalai University, India. (2014).
- Ananth S, Mathivanan V.** Histopathological changes in gill and kidney of *Ctenopharyngodon idella* exposed to arsenic trioxide. *International Journal of Current Research in Chemistry and Pharmaceutical Science*. (2014): 1(7): 1-7.
- Anees MA.** Intestinal pathology in a freshwater teleost, *Channa punctatus* exposed to sub lethal concentration of organophosphate pesticide. *Acta Physiol Lat Am*. (1976): 26:63-67.
- Barlas N.** Histopathological examination of gill, liver and kidney tissues of carp (*Cyprinus carpio* L, 1758) fish in the upper Sakarya River Basin. *Turk J Vet Anim Sci*. (1999): 23, 277-284.
- Cardoso EL, Chiarini-Gracia H, Ferreira RMA, Poli CR.** Morphological changes in the gills of *Lophiosilurus alexandri* exposed to unionized ammonia. *J Fish Biol*. (1996): 49,778-787.
- Cengiz EL, Unlü E, Balci K.** The histopathological effects of Thiodan on the liver and gut of mosquitofish, *Gambusia affinis*. *J Environ Sci Health B*. (2001): 36, 75-85.
- Couch JA.** Histopathological Effects of pesticides and Related Chemicals on Liver and Pancreas of Fish. In: *The Pathology of Fishes*, Riblin, W.E. and G.Migaki (Eds). University of Wisconsin Press, Madison Wisconsin. (1975): 515-558.
- Pandey S, Parvez S, Ansari RA, Ali M, Kaur M, Hayat F, Ahmad F, Raisuddin S.** Effects of exposure to multiple trace metals in biochemical, histological and ultrastructural features of gills of

a freshwater fish, *Channa punctata* (Bloch.). *Chemico- Biological Interactions*. (2008): 174: 183–192.

Richmonds C, Dutta HM. Histopathological changes induced by Malathion in the gills of bluegill *Lepomis macrochirus*. *Bull Environ Contam Toxicol*. (1989): 43, 123-130.

Vinodhini R, Narayana M. Heavy metal induced histopathological alterations in selected organs of the *Cyprinus carpio* L. *Int. J. Environ. Res*. (2009): 3(1): 95-100.

Yesudas Thangam. Effect of nitrite toxicity in carbohydrate metabolism to fresh water fish *Cirrhinus mrigala*. *Journal of Pharmacy and Biological Sciences*. (2014): 9(5): 3-11.