

Original Research Article

Formatted: Numbering: Continuous

HISTOPATHOLOGICAL CHANGES IN THE KIDNEY OF THE FRESHWATER FISH *NOTOPTERUS* *NOTOPTERUS* EXPOSED TO PROFENOFOS

Abstract

The impact of profenofos, an organophosphate pesticide on the kidney of Indian freshwater teleost fish *Notopterus notopterus* was evaluated. The experimental group was exposed to sublethal concentrations of profenofos at 7, 14 and 21 days. Histopathological changes due to the toxicity of 10 pesticide in experimental and control kidney of the fish was observed by sacrificed the animal every 7, 14 11 and 21 days. The kidneys were fixed in Bouin's solution, dehydrated in graded ethanol, infiltrated in 12 xylene, sectioned at 4-6 μ and stained in haematoxylin and eosin. Haemorrhage, oedema ??? and no effect 13 were however observed in control fishes. The author believes that Profenofos is significantly toxic to the 14 fish.

Comment [WU1]: iincomplete

Keywords: profenofos, histopathology, *Notopterus notopterus*, kidney, oedema

Introduction

Histopathology is promising field for research in aquatic toxicology as it provides the real picture 18 of the toxic of xenobiotics in vital functions of a living organism (Anees, 1976). Increasing the productivity 19 in the tropics and resulting human activities have caused serious damage to tropical ecosystems. The 20 degradation of terrestrial and aquatic ecosystems due to xenobiotics is a major concern and is a direct 21 result of the increased use of the synthetic chemicals such as pesticides in the productivity. 22 Organophosphorus pesticides are widely used in tropical agriculture. The toxicity of these pesticides is 23 based on inhibition of the enzyme acetylcholine esterase (AchE) and other enzymes like AAT and ALAT. 24 The extent of histopathological damages induced in the fish and the amount of cell damages in relation to 25 concentration of toxicants utilized in assessing the toxicity of pollutants. Couch (1975) stated that 26 gill, 26 liver, intestine and kidney of fishes are best suited organs for histopathological studies.

27
28 Previous histopathological studies of fish exposed to pollutants revealed that fish organs are 29 efficient indicators of water quality (Cardoso et al., 1996; Barlas 1999; Cengiz et al., 2001).

30 Profenofos is among the most toxic pesticide for aquatic life, especially to the fishes. Profenofos 31 is in general use for pest control in pigeon pea, cotton and vegetables.

32 However, there has been little information on the histopathological impact of Profenofos on the 33 fish kidney
33 Therefore, it was decided the need to determine the histopathological effects on the gills of in the fish N.
34 notopterus exposed to Profenofos.

35 35

36 36 **MATERIALS AND METHODS**

37 37 Adult fishes were collected from the Bhima reservoir. The fish were transferred to the laboratory
38 and they were acclimatized in glass aquaria 15 days prior to the experiment. Egg white and goat liver was
39 given to the fish daily and water of the aquaria was renewed alternately to avoid contamination.

40 The fishes were divided into two groups in glass aquaria. Fish were divided into two groups in
41 glass aquaria each. Ten fish were used for each group. Group I was exposed to commercial formulations
42 of the pesticide. The commercial concentrations tested were 0.07µg/L for Profenofos (Curacron 50% EC),
43 being the 1/10th of the 96h LC50 value. Group II was maintained in pesticide free water to serve as
44 control.

45 Both the experimental and control fish were sacrificed every 7, 14 and 21 days. Immediately after
46 decapitation the kidneys were removed and dropped into aqueous Bouin's fluid. After fixation for 24-30 hr,
47 tissues were dehydrated through a graded series of ethanol, cleared in xylene and infiltrated in paraffin 4-
48 6 µ thick sections were cut on rotary microtome and stained in counter stains (Haematoxylin and Eosin).
49 Pathological lesions were examined under compound microscope.

50

51

52

53

54

55

56

57

58

59

60

61

62

37 63

38 64

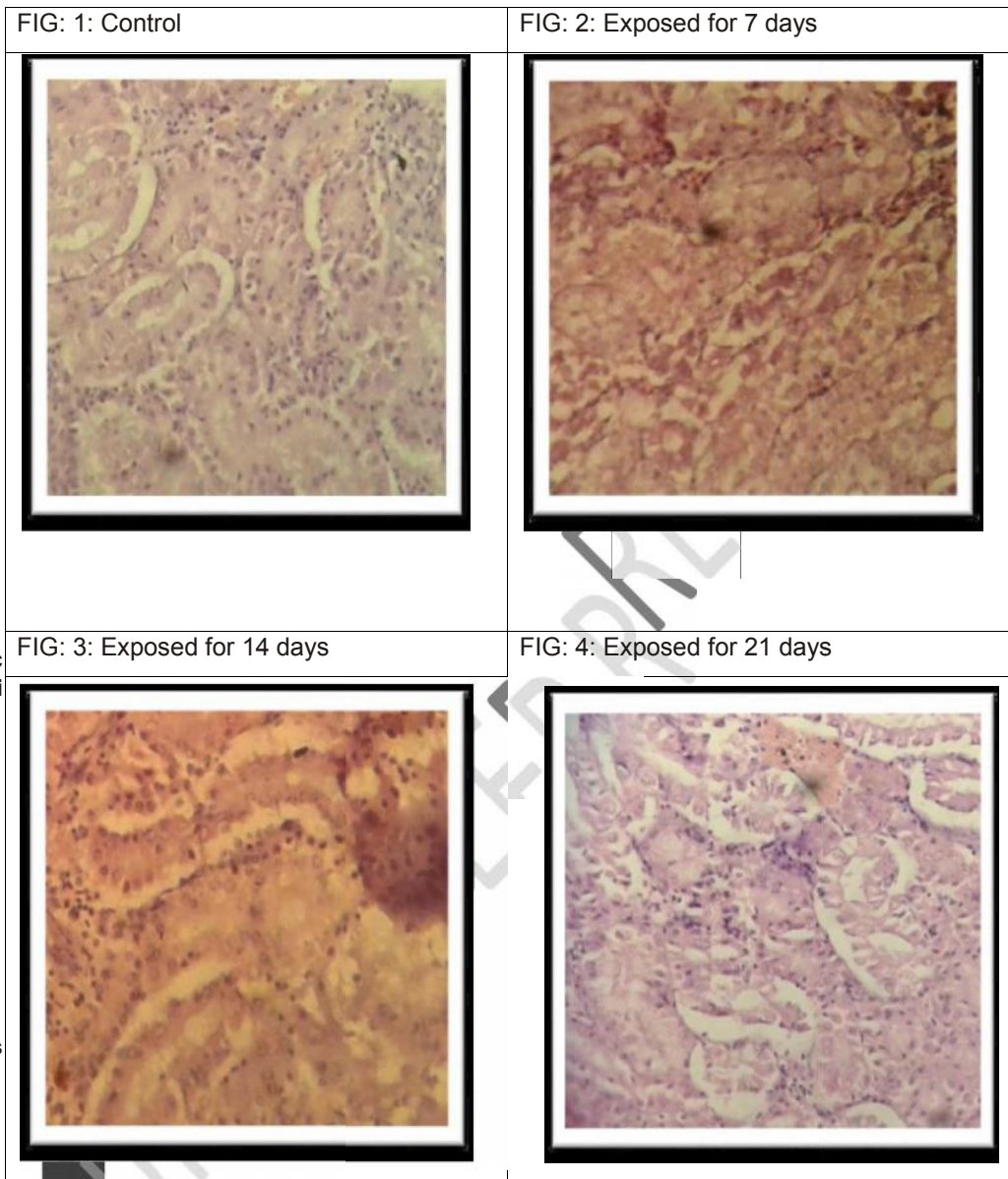
39 65

40 66

41 67

42 68

43



toxicant molecules from the body. Kidney is an 77 important organ of excretion and osmoregulation and it is highly susceptible to toxic substances of its high 78 blood supply and it is considered as a major target organ for toxicity impact (Ananth and Mathivanan, 79 2014). Fish kidney receives largest quantity of postbranchial blood, therefore renal lesions might be good 80 indicator of environmental pollution.

81 The histopathological changes were more evident in specimens exposed to Profenofos and were 82 not observed in the control fish. After exposure an excessive amount of mucus was observed over the

78 83 body of live specimens. It has been reported that the stress caused by the variations in the environment 84
79 and pathologic agents induced the proliferation of mucus cells and increased secretion (Richmonds and 85
80 Dutta, 1989; Cardoso *et al.*, 1996).

81 86 In this study, fig:2 after 7 days of exposure to sublethal concentration of Profenofos, showing
82 87 renal tubules with dilated lumen and fragmentation of glomeruli and haemorrhage, where as fig:3,
83 and 4.

84 8788 88 after 14 and 21 days exposed kidney showing necrosis, crumpled and pycnotic nucleus with
85 89 haemorrhage with dislocation of epithelial cells and the inflammatory cells develop necrosis
86 around the 90 border of tissue changed the normal shape of kidney, where as the section of
87 control kidney tissues fig:1, 91 exhibits an ordinary pattern with no abnormal changes in the cells .

88 92 These findings were similar to those of Yesudass Thangam (2014) in *Cirrhinus mrigala* exposed 93 to nitrate
89 and Anantha (2014) in *Ctenopharyngodon idella* exposed to arsenic trioxide.

90 94 According to Vinodhini and Narayanan, (2009) after exposed to heavy metal kidney exhibited the 95
91 presence of macrophages with lipofusion granules accumulated in the affected cells to the fish *Cyprinus* 96
92 *carpio*. The present experimental study, exhibited the presence of vacuoles in the tubules and necrosis of 97
93 kidney tubules in Profenofos (Curacron 50% EC) exposed fish, *N. notopterus*. A similar observation was 98 made
94 in the kidney of *Channa punctatus* exposed to heavy metal by Pandey *et al.*, (2008) and *Cirrhinus* 99
95 *mrigala* exposed to nitrate by Yasudas Thangam (2014).

96 100

97 101 CONCLUSION

98 102 Present study indicated that exposure to sublethal concentration Profenofos (Curacron 50% EC) 103 caused
99 histological alterations in the kidney of the freshwater fish *N. notopterus*.

100 104

101 105

102 106

103 107 REFERENCES

104 108

105 109 Anantha S. Studies on the impact of arsenic trioxide on certain aspects in selected tissues of 110 freshwater
106 fish *Ctenopharyngodon idella*, Ph. D. thesis, Annamalai University, India. (2014).

107 111

108 112 Ananth S, Mathivanan V. Histopathological changes in gill and kidney of *Ctenopharyngodon* 113
109 *idella* exposed to arsenic trioxide. *International Journal of Current Research in Chemistry and* 114
110 *Pharmaceutical Science*. (2014): 1(7): 1-7.

111 115

112 116 Anees MA. Intestinal pathology in a freshwater teleost, *Channa punctatus* exposed to sub lethal 117
113 concentration of organophosphate pesticide. *Acta Physiol Lat Am*. (1976): 26:63-67.

Formatted: Font: (Default) Calibri, 11 pt,
Font color: Black

114 118
115 119 **Barlas N.** Histopathological examination of gill, liver and kidney tissues of carp (*Cyprinus carpio* 120 L,1758)
116 fish in the upper Sakarya River Basin. *Turk J Vet Anim Sci.* (1999): 23, 277-284.
117 121
118 122 **Cardoso EL, Chiarini-Gracia H, Ferreira RMA, Poli CR.** Morphological changes in the gills of 123
119 *Lophiosilurus alexandri* exposed to unionized ammonia. *J Fish Biol.* (1996): 49,778-787.
120 124
121 125 **Cengiz EL, Unlü E, Balci K.** The histopathological effects of Thiodan on the liver and gut of 126
122 mosquitofish, *Gambusia affinis*. *J Environ Sci Health B.* (2001): 36,75-85.
123 127
124 128 **Couch JA.** Histopathological Effects of pesticides and Related Chemicals on Liver and Pancreas 129 of Fish.
125 In : *The Pathology of Fishes*, Riblin, W.E. and G.Migaki (Eds). University of Wisconsin Press, 130 Madison
126 Wisconsin. (1975): 515-558.
127 131
128 132 **Pandey S, Parvez S, Ansari RA, Ali M, Kaur M, Hayat F, Ahmad F, Raisuddin S.** Effects of
129 133 exposure to multiple trace metals in biochemical, histological and ultrastructural features of gills of
130 134 a freshwater fish, *Channa punctata* (Bloch.). *Chemico- Biological Interactions.* (2008): 174: 183–
131 135 192.
132 136 **Richmonds C, Dutta HM.** Histopathological changes induced by malathion in the gills of bluegill
133 137 *Lepomis macrochirus*. *Bull Environ Contam Toxicol.* (1989): 43, 123-130.
134 138
135 139
136 140 **Vinodhini R, Narayana M.** Heavy metal induced histopathological alterations in selected organs 141 of the
137 *Cyprinus carpio* L. *Int. J. Environ. Res.* (2009): 3(1): 95-100.
138 142
139 143 **Yesudas Thangam.** Effect of nitrite toxicity in carbohydrate metabolism to fresh water fish 144 *Cirrhinus*
140 *mrigala*. *Journal of Pharmacy and Biological Sciences.* (2014): 9(5): 3-11.
141 145

